**DATE PRESENTING CLINICAL SIGNS**

9.22.2022

P has history of elevated liver values also had dental disease and had a dark Melanic Mass in oral cavity - pathology is pending. Has discussed risks of anesthesia with unknown liver issues, O wanted to proceed. Morning of procedure did a fast scan of abdomen with the ultrasound and noted normal liver architecture, but very distended GB measured ~7cm with increased echogenic debris. O had not noted any changes in behavior prior that was communicated to me before procedure. P had some diarrhea in cage - suspected due to stress, heart and lungs WNL, proceeded with Dental and mass removal. handled anesthesia and surgery well, went home stable. At home P was lethargic but ok at first. O called concerned bc P would not eat and unable to get rx antibiotics in, p cam in today with vomiting and bloody diarrhea, collapsed in waiting room. P painful / tense in abdomen, Fast scan shoed increased inflammation and trace free fluid in cranial abdomen. P shocky, getting stabilized with fluids, responded to cerenia

PATIENT

Miss Maisy DiLutis

SPECIES

Canine

BREED

Scottish Terrier

SEX

Spayed Female

AGE

5/3/2010

WEIGHT

31.3lbs

INTERPRETED BY

Andrea Nicastro, DMV,
 Diplomate DACVIM
 (Small Animal
 Internal Medicine)

HOSPITAL NAME

Northwind AH

REFERRING VET

Dr. Repsher

INVOICE

11687

Current Medications: Rxed clavamox, metronidazole and ursodiol - P has not taken anything bc was not eating iv Cerenia given today

Lab Results: ALT 172, ALP 2810, GGT 23, SDMA 15, BUN 46, Creat WNL, Calcium 12.1, Potassium 5.9.
 Date of Previous IntraPet Ultrasound: No previous.

Sedation: Not required to complete full diagnostic ultrasound.

Stat Report: Not requested.

Imaging Performed By: Andi Parkinson, BS, RDMS.

ULTRASONOGRAPHIC EXAMINATION OF THE ABDOMEN**Urinary System**

The **urinary bladder** is contracted. The wall is of appropriate thickness for the level of repletion. No cystic calculi are observed. The visible portion of the proximal urethra is normal.

The **left kidney** is normal size (5.49 cm in length) with a normal shape, smooth peripheral margins, and normal internal architecture. There is mild to moderate loss of corticomedullary distinction. Several hyperechoic shadowing diverticular foci are observed. There is no evidence of pyelectasia, infarcts or hydronephrosis.

The **right kidney** is normal size (5.64 cm in length); with a normal shape, smooth peripheral margins, and normal internal architecture. There is mild to moderate loss of corticomedullary distinction. Several hyperechoic shadowing diverticular foci are observed. There is no evidence of pyelectasia, infarcts or hydronephrosis.

Adrenal Glands

The **left adrenal gland** is normal size (0.63 cm at cranial pole) (0.68 cm at caudal pole) (2.12 cm in length); normal shape; homogenous parenchyma. The glandular echogenicity and detail are unremarkable. Capsule, cortex, and medullary definition are normal. The phrenicoabdominal vein and surrounding vasculature are normal.

The **right adrenal gland** is normal size (0.98 cm at cranial pole) (0.63 cm at caudal pole); normal shape; homogenous parenchyma. The glandular echogenicity and detail are unremarkable. Capsule, cortex, and medullary definition are normal. The phrenicoabdominal vein and surrounding vasculature are normal.

Spleen

The **spleen** is normal in size (1.88 cm in width at the level of the hilus) with a normal capsular contour. There is appropriate echogenicity and echotexture. No focal lesions are observed. Splenic vasculature is normal.

Liver

The **liver** is subjectively enlarged with swollen peripheral contours. The parenchyma is isoechoic relative to the spleen. A 2.67 cm hypoechoic to heterogenous nodule/mass is observed deep on the left side. In addition, a 3.19 cm isoechoic nodule is observed in the region of the right medial lobe. The remaining parenchyma is homogenous. Hepatic vasculature and intrahepatic biliary tracts are of normal volume with no evidence of congestion.

The **gall bladder** is severely distended. The wall is normal in thickness. The lumen is filled with aggregated, suspended sludge in a stellate pattern. The mesentery surrounding the gall bladder is hyperechoic. Free fluid is present adjacent to the gall bladder wall.

Gastrointestinal

The **gastric lumen** is not distended. The gastric wall is normal in thickness with a normal layering pattern. The small intestinal lumen is not dilated. The small intestinal wall thickness is normal with a normal layering pattern and appropriate mural detail. Discreet masses are not identified. The colonic wall is normal. There is no evidence of an obstructive pattern.

Pancreas

The base/right limb is prominent to mildly enlarged with minimal deviation from the normal peripheral contours. The parenchyma is mildly hypoechoic relative to surrounding omental fat and subtly mottled in appearance. No distinct focal lesions are observed. The pancreatic duct is not overtly dilated.

Free Abdomen

A moderate amount of echogenic free fluid is present. The mesentery throughout the abdomen, particularly in the cranial aspect is hyperechoic. The abdominal **lymph nodes** are normal/not visible.

ULTRASONOGRAPHIC FINDINGS

Primary Findings

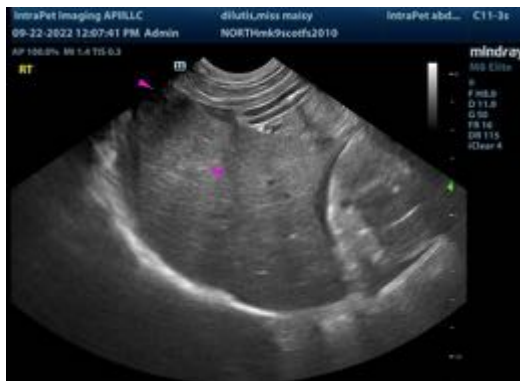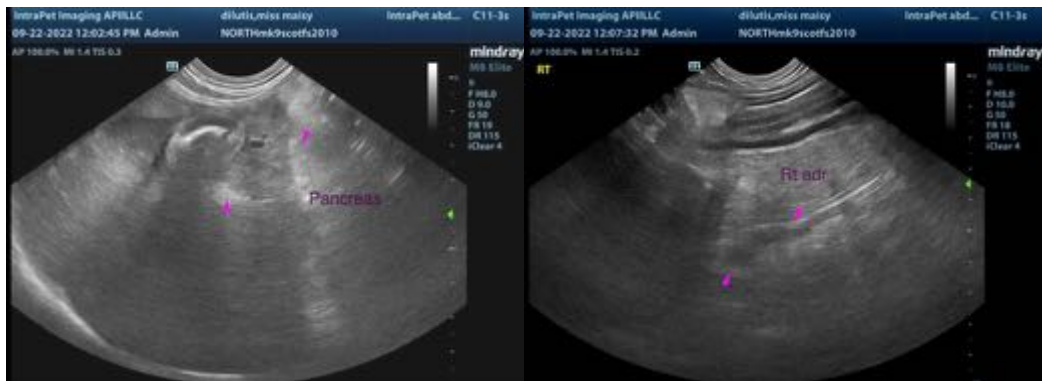
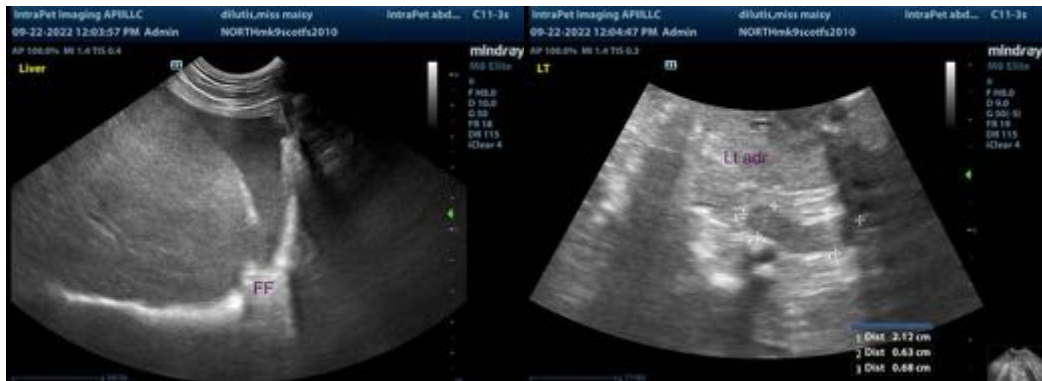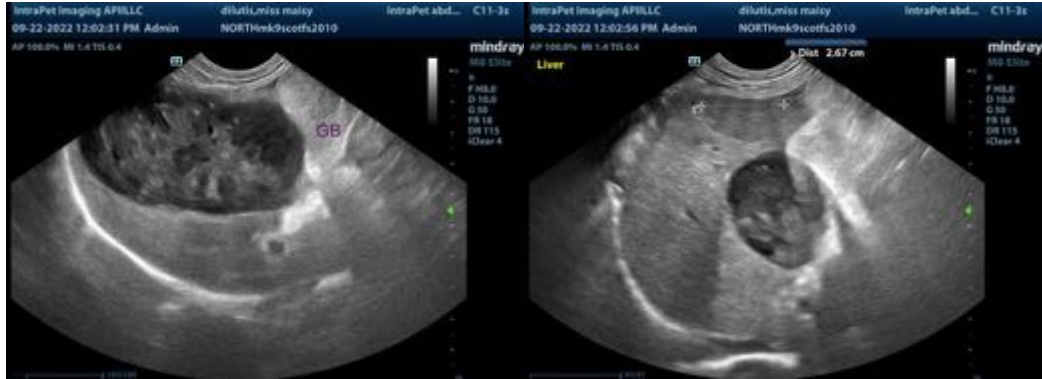
- The gall bladder changes are consistent with a fully formed mucocele. Adjacent peritonitis is present. Gall bladder rupture with bile/septic peritonitis is suspected.
- The hepatic nodules could be consistent with a benign process (i.e., regenerative nodular hyperplasia) or emerging tumors. A benign process is favored. The diffuse hepatic parenchymal changes trend toward the benign (i.e., vacuolar hepatopathy, inflammatory disease) with a lower possibility malignancy.

Secondary Findings

- The pancreatic changes are suggestive of pancreatitis with age-related remodeling.
- Bilateral degenerative renal changes with dystrophic mineralization

INTERPRETATION OF THE FINDINGS & FURTHER RECOMMENDATIONS

No recommendations. The patient was euthanized following this study.



The information and recommendations provided are based on the images presented by the referring veterinarian/sonographer. No evaluation can be communicated regarding pathology that was not visible in the image/video clips provided.

Thank you for this referral. If the clinical or image interpretation does not parallel your findings or if I can be of any further assistance, please contact me.

Andrea Nicastro, MPH, DVM, Diplomate DACVIM (Small Animal Internal Medicine)
info@SonoPath.com